

## A rare case report: Castleman's disease

Dr. Manvee Tomar<sup>1</sup>, Dr. Kapil Kumar Singh<sup>2</sup>, Dr. Parmanand Rai<sup>3</sup>

<sup>1</sup> Senior Resident, Department of Otorhinolaryngology, LLRM, Medical College, Meerut, Uttar Pradesh, India

<sup>2</sup> Head of Department, Department of Otorhinolaryngology, LLRM, Medical College, Meerut, Uttar Pradesh, India

<sup>3</sup> Junior Resident, Department of Otorhinolaryngology, LLRM, Medical College, Meerut, Uttar Pradesh, India

### Abstract

Castleman's disease is a rare clinico-pathological entity characterized by non-neoplastic lymph node hypertrophy. Its incidence and etiology is not known, but it has been found in association with Kaposi's Sarcoma. We report a case of 34 years old female patient with history of solitary neck swelling (left Neck) for 10 months without any other presenting symptoms in the nose and throat. The neck node was present at level 2b, measuring 3x2cm, firm, painless, non-tender and mobile beneath the left Sternocleidomastoid muscle.

Lymph node histopathological biopsy revealed Castleman's disease. USG Whole abdomen, Chest X Ray, CECT Thorax were normal. This case report highlights the clinical, histological aspects of Castleman's disease.

**Keywords:** castleman's disease, cervical lymph node, hyaline vascular type

### Introduction

Castleman's disease is a clinicopathological entity characterized by non-neoplastic lymph node hypertrophy and histologically characterized by angiofollicular lymph node hyperplasia. Castleman *et al.* first described it in 1956 in a group of patients with localized benign lymphadenopathy [1]. The incidence is not known and can occur at any age but mostly reported in adults in the literature. Etiology of this disease is not known, though it has been found in association with Kaposi's sarcoma.

### Synonyms

- Angiofollicular lymph node hyperplasia
- Angiofollicular lymphoid hyperplasia
- Giant lymph node hyperplasia
- Lymphoid hamartoma
- Benign lymphoma

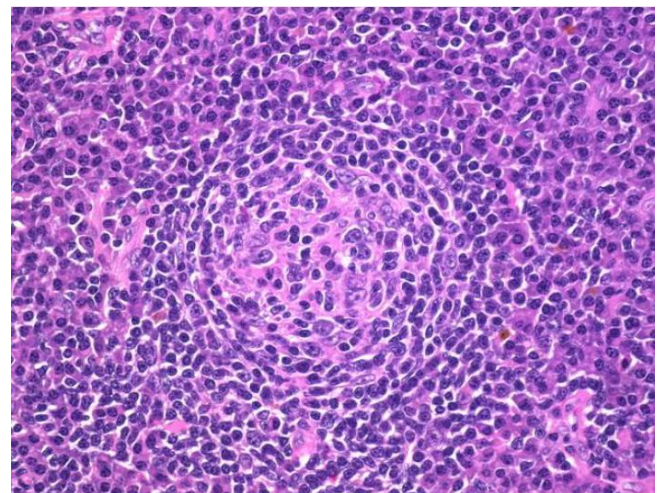
### Case Report

A 34 years old female patient presented to ENT OPD on January 2019 with history of a solitary, firm swelling in left side of neck of 10 months duration. Examination of neck revealed a single swelling on the left side of neck, level 2b measuring around 3 x2 cm which was firm, non-tender, mobile, situated medial to the sternocleidomastoid muscle. Examination of ear, nose, oral cavity and oropharynx and larynx revealed no abnormal findings. General physical examination was done and no other group of lymph nodes found to be enlarged.

Blood examination revealed Hb-15.1 gm/dl, RBC-5.37X10<sup>6</sup>/dl, TLC-6,040 cell/cumm, ESR-15mm/hr, Differential count revealed N 64%, L27%, M3%, E4%. Peripheral blood picture revealed normocytic normochromic cells. HBsAg, HCVAb, HIV Test were negative.

FNAC showed single, firm, non-tender, mobile swelling over the left side of neck (level 2b) measuring 3x 2 cm in diameter. Aspiration smears are cellular and showed a

heterogenous population of lymphoid cells in various stages of maturation composed predominantly of mature small lymphocytes along with tangible body macrophages in a background of lymphoglandular bodies. Few clusters of macrophages were also noted. Features were suggestive of non-specific reactive lymphadenitis.



**Fig 1:** Slide showing aspiration cytology of non-specific reactive lymphadenitis.

USG Neck showed large homogenous hypoechoic solid node of size 4.9x3.17x1.78 cm with moderate vascularity in left level 2b noted suggestive of malignant node with few prominent jugular node. CECT NECK showed a well-defined oval mass lesion measuring 3.2x2.5x1.6cm noted in the left side of neck situated medial to the sternocleidomastoid muscles and posterolateral to the carotid sheath with loss of delineation with carotid sheath, S/O Nerve Sheath Tumour (Paraganglioma). CECT Thorax, USG whole abdomen, CRP (C-Reactive Protein) were normal. Since there was no conclusive evidence, an excision

biopsy was planned to know the exact nature of the disease. The lymph node excised was sent for histopathological examination to 2 centres.

**Histopathology**

Specimen: Excision biopsy, swelling, left neck for HPE.  
 Gross: Specimen, labelled nerve sheath tumour, consists of a bisected half of soft tissue measuring 3.5x3x2 cm. C/S-firm, grey white and fleshy.  
 Microscopic: Multiple sections studied from the entire cut surface of the specimen received show lymph node displaying numerous regressively transformed germinal centres. Majority of the lymphoid follicles are traversed by hyalinised blood vessels imparting a lollipop appearance. The mantle zones are thickened and show lymphocytes in a concentric fashion imparting onion skin appearance. The interfollicular spaces are expanded and show numerous arborising capillaries and note is made of scattered plasma cells. Occasional atypical dendritic cells are identified. There is no evidence of granulomas of nerve sheath tumour in any of the sections studied. Features are Castleman’s disease-hyaline vascular variant.

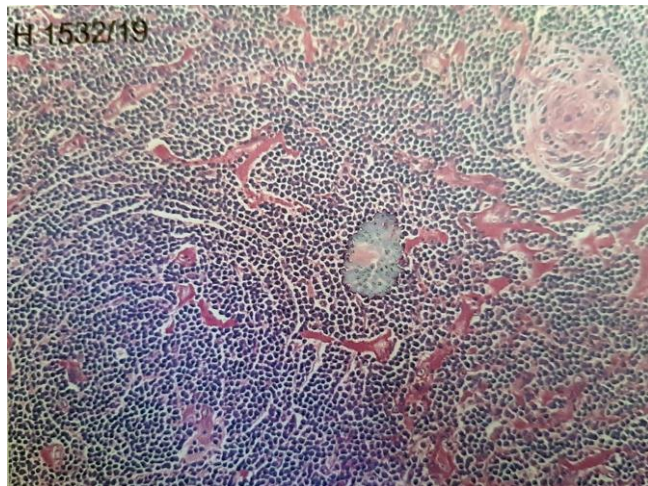


Fig 2

**Impression:** Castleman’s disease- hyaline vascular variant. Patient was discharged with advice for regular follow-up every 1 month.

**Discussion**

Castleman's disease (CD) is lymphoproliferative disorder which is histologically characterised by angiofollicular lymph-node hypertrophy [2].

**Clinically 2 types identified**

1. Localized as first described by Castleman, which is more common.
2. Multicentric disease (MCD) with involvement of several sites, which was first described by Gaba *et al.* in 1972 [3].

**Histologically 3 types identified**

- The hyaline vascular type: Characterized by lymphoid follicular proliferation at different levels of maturity forming a layered or ‘onionskin’ pattern surrounding a hyalinised vessel at the center of the follicle. These vessels are often prominent and reactive. This type is more commonly seen in the localized form.

- The plasma cell variant: This variant has sheets of mature plasma cells within the interfollicular tissues surrounding larger germinal centers and has significantly less vascularity. This is commonly seen in the multicentric form of the disease.
- Mixed variant: A third histological variant showing a mixed picture can also be seen in MCD.

Localized CD is, by definition, localised to one site. It features lymphoid hyperplasia associated with excessive angiogenesis [4]. It is asymptomatic in over 50% of patients [5], and is often discovered incidentally. Histological diagnosis requires lymph-node biopsy.

Multicentric CD is characterized by a predominantly lymphadenopathic presentation consistently involving peripheral lymph-nodes and manifestations of multisystem involvement. It is considered as a systemic B cell lymphoproliferation, probably arising in immunoregulatory deficit, and resulting in the outgrowth of clonal B-cell populations [6]. It is always symptomatic. Symptoms, primarily a consequence of elevated Interleukin-6 (IL-6) production, are asthenia (65%), weight loss (67%) and fever (69%) [7]. Polyadenopathy is common (84%) with a mean of four sites involved and is often associated with hepatosplenomegaly [6]. Histological diagnosis is made upon biopsy of an excised peripheral lymph-node.

A POEMS (Peripheral polyneuropathy, Organomegaly, Endocrinopathy, Monoclonal gammopathy (M-Protein) and Skin signs) syndrome [8]. Is observed in 24% of patients [9]. Progression to malignant lymphoma in MCD associated with HIV is frequent, and within a prospective cohort study [10]. Of 60 HIV-infected patients with MCD, and a follow-up period of 20 months, 14 patients (23%) developed HHV8-associated non-Hodgkin lymphoma.

**Etiology**

The aetiology of Castleman's disease is poorly understood and no genetic or toxic factor has so far been identified. Several studies have suggested the role of human herpes virus 8 (HHV-8), already implicated in Kaposi's sarcoma. In MCD, HHV-8 sequences were identified in 60–100% of patients infected with HIV and in 20–41% in those who were not [10, 11]. These findings suggest two possibilities concerning the genesis of CD: (i) the opportunistic presence of HHV-8, favoured by immune perturbations; and (ii) the direct pathogenic role of HHV-8, in association with dysregulation of cytokine.

**Clinical features and investigations**

The localized form of the disease is mostly asymptomatic with a single site lymph node enlargement. The sites commonly involved are abdomen, peripheral lymph nodes and the mediastinum. It is often discovered incidentally during routine examination, chest X rays or due to discomfort secondary to local compression as is in our case described above. Diagnosis is made by histological analysis of the lymph node biopsy to distinguish it from a thymoma. MCD, however, presents with systemic symptoms along with multiple lymph node hyperplasia. The systemic symptoms are thought to be primarily a consequence of elevated Interleukin-6 (IL-6) production. They present as asthenia, weight loss, fever, polyadenopathy with a mean of four-site involvement and is often associated with hepatosplenomegaly.

Some forms of MCD have been found in association with Kaposi's Sarcoma. HIV positive MCD shows an increased prevalence of pulmonary symptoms and can be differentiated from other types of HIV-associated systemic lymphoproliferative disorders. There is also an increased progression of HIV positive MCD to HHV 8 associated malignant non-Hodgkin's lymphoma [3].

### Investigations

Routine blood tests usually reveal anaemia, raised ESR, thrombocytopenia and raised polyclonal gamma globulins. Identifying an immunophenotypically varied population of B-lymphocytes with polyclonal surface and cytoplasmic immunoglobulin markers helps to confirm the diagnosis of Castleman's disease and differentiate it from lymphoma.<sup>4</sup> HIV testing should be undertaken with the patient's permission. Herpes Virus (HHV 8/KSHV) has been isolated in almost all cases of HIV associated Kaposi's sarcoma MCD and some non HIV Kaposi's sarcoma MCD prompting tests for KSHV3. Histological examination of the biopsied lymph node is essential for the diagnosis.

### Treatment

Localized CD usually has a good prognosis and requires surgical excision of the enlarged lymph node with no further treatment. The patients generally remain asymptomatic thereafter.

MCD however tends to have a variable prognosis with no documented treatment consensus. A variety of combination treatments have been tried with surgical excision, chemotherapy and steroids. In patients with associated Kaposi's sarcoma monthly polychemotherapy (e.g. cyclophosphamide, vincristine, doxorubicin and prednisone) has been tried with limited success. Anti-IL6 antibodies have shown success with systemic symptoms, as with steroids. Most treatment modalities involve immunosuppression, increasing the chances of opportunistic infections. Recent suggestions are that treatment with the anti-herpes virus drug ganciclovir or the antiCD20 B cell monoclonal antibody, rituximab, may markedly improve outcome.

### Conclusion

We decided to publish this case report in order to highlight the importance of obtaining a definitive histological diagnosis in patients presenting with lymphadenopathy without systemic symptoms. This case report is going to publish for the first time in LLRM. Though clinically synonymous with lymphoma, it is an entity that is distinct from malignant lymphoproliferative disorders histologically and prognostically. There is no significant treatment for localised Castleman's disease after excision, and hence patient was advised regular follow-up at interval of 1 month.

**Conflicts of interest:** There are no conflicts of interest

### References

1. Castleman B, Iverson I, Menendez VP. Localized mediastinal lymph node hyperplasia resembling thymoma. *Cancer* 1956; 9:822-30.
2. Frizzera G. Castleman's disease and related disorders. *Semin Diagn Pathol* 1988; 5(4):346-364.
3. Gaba AR, Stein RS, Sweet DL, Variakojis D. Multicentric giant lymph node hyperplasia. *Am J Clin*

- Pathol. 1978; 69:86-90.
4. Oksenhendler E, Boulanger E, Galicier L, *et al.* High incidence of Kaposi sarcoma associated herpesvirus-related non-Hodgkin lymphoma in patients with HIV infection and multicentric Castleman disease. *Blood* 2002; 99(7):2331-6.
5. Herrada J, Cabanillas F, Rice L, Manning J, Pugh W. The clinical behaviour of localized and multicentric Castleman disease. *Ann Intern Med.* 1998; 128(8):657-62.
6. McCarty MJ, Svetislava JV, Banks PM, *et al.* Angiofollicular lymph node hyperplasia (Castleman's disease). *Cancer Treat Rev* 1995; 21:291-310.
7. Rose C, Mahieu M, Hachulla E, Facon T, Hatron PY, Bauters F, *et al.* Le POEMS syndrome. *Rev Med Interne.* 1997; 18(7):553-62.
8. Sarrot-Reyauld F. Castleman's Disease; Orphanet encyclopedia, August 2001. (<http://www.orpha.net/data/patho/GB/ukcastleman.pdf>).
9. Oksenhendler E, Boulanger E, Galicier L, Du MQ, Dupin N, Diss TC, *et al.* High incidence of Kaposi sarcoma-associated herpesvirus-related non-Hodgkin lymphoma in patients with HIV infection and multicentric Castleman disease. *Blood* 2002; 99(7):2331-6.
10. Sarrot-Reynauld F, Morand P, Buisson M. Groupe francais d'etude de la maladie de Castleman. Maladie de Castleman et infection par le virus HHV-8. *Rev Med Interne* 1998; 19(3):413.
11. Soulier J, Grollet L, Oksenhendler E, Cacoub P, Cazals-Hatem D, Babinet P, *et al.* Kaposi's sarcoma-associated herpesvirus-like DNA sequences in multicentric Castleman's disease. *Blood* 1995; 86(4):1276-80.